

Onychomadesis: Clinical Image

Reza Bidaki¹, Narges Ghanei², Ardakani ME²

¹Research Center of Addiction and Behavioral Sciences, Shahid Sadoughi University of Medical Sciences, Yazd, Iran

²Department of Dermatology, Shahid Sadoughi University of Medical Sciences, Yazd, Iran

Corresponding author: Narges Ghanei, Department of Dermatology, Shahid Sadoughi University of Medical Sciences, Yazd, Iran, Tel: +983538220000; Email: Nargesgh73@yahoo.com

Received date: Mar 04, 2016; **Accepted date:** Mar 06, 2016; **Published date:** Mar 11, 2016

Copyright: © 2016 Bidaki R, et al. This is an open-access article distributed under the terms of the Creative Commons Attribution License, which permits unrestricted use, distribution, and reproduction in any medium, provided the original author and source are credited.

Citation: Bidaki R, Ghanei N, Ardakani ME. Onychomadesis: Clinical Image. Skin Dis Skin Care. 2016, 1: 1.

Arrest of nail matrix is commonly occurred following some of systemic diseases, psychological stress or drug exposures. When nail matrix arrest partially produce transverse ridging of the nail plate (Beau's lines), and onychomadesis is longer-term nail growth stopping or complete nail matrix arrest causes to nail shedding from the proximal part [1]. All three parents were anxious but we haven't document about the role of stress anxiety as trigger or reinforce of this rare disease in children.

Onychomadesis is presented in three patients as a result of hand-foot-mouth disease. All children showed history of infection as fever and upper respiratory tract infection. They involved with oral rash and cutaneous rash in buttock, hands and feet.

Keywords: Onychomadesis; Nail; Stress; Anxiety

Case 1

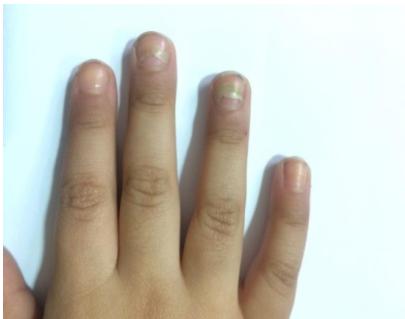


Figure 1: Onychomadesis in hand following hand-foot-mouth disease (HFMD) in a 28 month-old boy.

Case 2

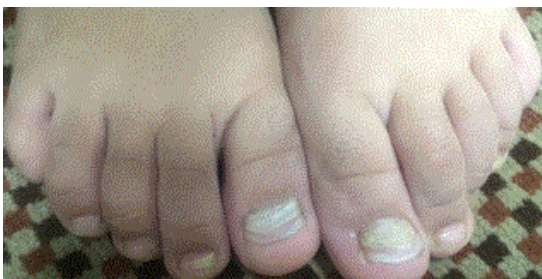


Figure 2: Onychomadesis in feet following hand-foot-mouth disease (HFMD) in a 4 year-old boy.

Case 3

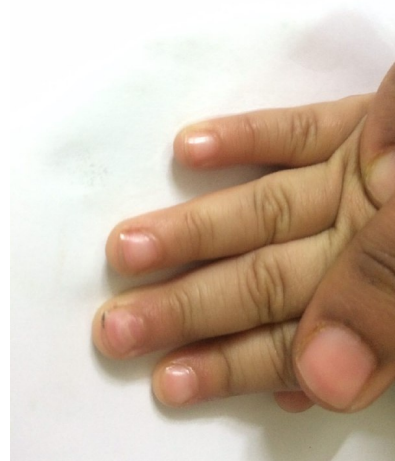

Figure 3: Onychomadesis in hand following hand-foot-mouth disease (HFMD) in a 14 month-old girl.

References

1. Bodman MA (1995) Miscellaneous nail presentations. Clin Pediatr Med Surg 12: 327-347.